

Thomas M. Stoll
Gilles Dubois
Othmar Schwarzenbach

The dynamic neutralization system for the spine: a multi-center study of a novel non-fusion system

Received: 8 April 2002
Accepted: 30 April 2002
Published online: 10 September 2002
© Springer-Verlag 2002

Abstract Various forms of lumbar instability require a surgical stabilization. As an alternative to fusion, a mobile, dynamic stabilization restricting segmental motion would be advantageous in various indications, allowing greater physiological function and reducing the inherent disadvantages of rigid instrumentation and fusion. The dynamic neutralization system for the spine (Dynesys) is a pedicle screw system for mobile stabilization, consisting of titanium alloy screws connected by an elastic synthetic compound, controlling motion in any plane (non-fusion system). This prospective, multi-center study evaluated the safety and efficacy of Dynesys in the treatment of lumbar instability conditions, evaluating pre- and post-operative pain, function, and radiological data on a consecutive series of 83 patients. Indications consisted of unstable segmental conditions, mainly combined with spinal stenosis (60.2%) and with degenerative discopathy (24.1%), in some cases with disc herniation (8.4%), and with revision surgery (6.0%). Thirty-nine patients additionally had degenerative spondylolisthesis, and 30 patients had undergone previous lumbar surgery. In 56 patients instrumentation was combined with direct decompression. The mean age at operation was 58.2 (range 26.8–85.3) years; the mean follow-up time was 38.1 months (range 11.2–79.1 months). There were nine complications unrelated

to the implant, and one due to a screw malplacement. Four of them required an early surgical reintervention. Additional lumbar surgery in the follow-up period included: implant removal and conversion into spinal fusion with rigid instrumentation for persisting pain in three cases, laminectomy of an index segment in one case and screw removal due to loosening in one case. In seven cases, radiological signs of screw loosening were observed. In seven cases, adjacent segment degeneration necessitated further surgery. Mean pain and function scores improved significantly from baseline to follow-up, as follows: back pain scale from 7.4 to 3.1, leg pain scale from 6.9 to 2.4, and Oswestry Disability Index from 55.4% to 22.9%. These study results compare well with those obtained by conventional procedures; in addition to which, mobile stabilization is less invasive than fusion. Long-term screw fixation is dependent on correct screw dimension and proper screw positioning. The natural course of polysegmental disease in some cases necessitates further surgery as the disease progresses. Dynamic neutralization proved to be a safe and effective alternative in the treatment of unstable lumbar conditions.

Keywords Lumbar spine · Surgical treatment · Non-fusion · Instrumentation · Instability

T.M. Stoll (✉)
Department of Spinal Surgery,
Bethesda Spital,
Gellertstrasse 144,
4020 Basel, Switzerland
e-mail: thomas.stoll@bethesda.ch,
Tel.: +41-61-3152333,
Fax: +41-61-3152338

G. Dubois
Nouvelle Clinique de l'Union,
St. Jean, France

O. Schwarzenbach
Spital Thun-Simmatal, Thun, Switzerland

Introduction

Spinal instrumentation has always pursued one main aim: to stabilize the motion segment. Stabilization is aimed at stopping noxious motion, holding position, and preventing deformity. It has always addressed the two main sequelae of spinal pathology: pain and dysfunction by neurocompression as well as pain by loading and moving pain-generating tissues such as the disc, facet joints, ligaments, muscles or fracture fragments [30]. In the individual life cycle, degenerative spondylosis frequently leads to instability, as Kirkaldy-Willis and Farfan [22] depicted well with their concept of three phases of degenerative spondylosis: (1) dysfunction, (2) unstable phase, (3) re-stabilization. This concept is supported by Husson et al. [19]. Thus, spinal instrumentation has always aimed at dealing with some form of instability.

The dynamic neutralization system for the spine (Dynesys) is a non-fusion pedicle screw system for the stabilization of the lumbar spine [8, 11]. It is designed for uni- or multisegmental use. It aims at pathological conditions with some form of segmental instability and various forms of sequelae. Dynesys was developed based upon all the current knowledge of and experience with conventional rigid pedicle systems. It establishes a mobile load transfer and controls motion of the segment in all planes, whilst inducing stability. Thus, the bilateral implant system controls motion in all planes. Stability with controlled segmental motion is established, achieving a more physiological condition as compared with the sole decompression of an unstable segment or as compared with fusion of such a segment. In connection with decompressive procedures, the system re-establishes stability and avoids iatrogenic instability. Some disadvantages of fusion could be expected to be overcome, for instance the “transition syndrome” caused by overloading adjacent segments or increased invasiveness. The first implantation of this novel system was performed in 1994 by one of the authors of the present paper, G. D., who is the author of the system.

The study presented here was performed with the primary objective of proving the safety and efficacy of this novel posterior instrumentation system. It is a multi-center study reflecting the first clinical experience with this implant based upon a prospective protocol and including frequent indications for surgery, for which conventional procedures would otherwise have been applied.

The results should be compared to series of patients with similar pathologies, but surgically treated differently, be it by direct decompression or some fusion procedure.

Materials and methods

Patients

The study covers 83 consecutive patients who underwent surgery with Dynesys instrumentation performed by the three authors. At two centers (T.S., O.S.) it included the first consecutive series.

Table 1 Indications

| | N | % |
|---|----|------|
| Primary diagnosis | | |
| Spinal stenosis | 50 | 60.2 |
| Degenerative discopathy (DDD) | 20 | 24.1 |
| Disc herniation | 7 | 8.4 |
| Revision surgery | 5 | 6.0 |
| Other | 1 | 1.2 |
| Total | 83 | 100 |
| Secondary diagnosis | | |
| Degenerative spondylolisthesis | 39 | 47.0 |
| Previous therapeutic lumbar interventions | 30 | 36.1 |

Patient selection: inclusion criteria

The selection criteria for the procedure included patients with neurogenic, radicular pain and/or chronic low-back pain resistant to any conservative treatment, presenting with some form of instability, where stabilization was judged to be beneficial. Most of these patients would have undergone fusion if Dynesys had not been available. Some would have undergone only a direct decompression. The range of indications was determined upon the theoretical concept and on an understanding of the mechanical qualities of the implant, gained from existing clinical and biomechanical knowledge and from biomechanical tests [8, 11].

The primary indications (Table 1) were: spinal stenosis in 50 patients, degenerative discopathy in 20 patients, disc herniation in 7 patients and revision surgery in 5 patients. Spinal stenosis was often combined with other secondary pathologies: with degenerative olisthesis in 29 patients, with degenerative olisthesis and degenerative scoliosis in 3 patients and with a degenerative scoliosis in another 3 patients.

The average age at operation was 58.2 (range 26.8–85.3) years. The gender distribution was 49 women, 34 men. Figure 1, Fig. 2, Fig. 3 and Fig. 4 show cases demonstrating typical pathologies for which Dynesys was applied.

Preoperative assessment

The preoperative assessment included patient history, physical assessment, neurological assessment and the assessment of imaging. Imaging included antero-posterior, lateral and dynamic lateral X-rays as well as at least one form of additional imaging (myelography, MRI, CT-scan, discography). The Prolo score [32] was assessed. The patient answered the Oswestry Questionnaire (Oswestry Disability Index) and two pain score questionnaires, one for axial low back pain and one for leg pain.

Assessment at follow-up

The assessment at follow-up was performed by independent examiners. It included the same protocol as the preoperative assessment, with the exception of the additional imaging studies.

Surgical technique

Surgery was performed by a mid-line approach and instrumentation by the surgical technique for Dynesys, with the pedicle screw positioned at the conventional (Magerl) site. Decompression, where indicated, was performed directly by undercutting laminae

Fig. 1 A Magnetic resonance (MR) image of a 39-year-old woman presenting with low-back pain and S1 root pain, which demonstrates disc disease at L4/5, and L5/S1; L4/5 with annular tear, L5/S1 with medial herniation. Both discs produced positive provocative pain sign on discography.

B Radiographs of the same patient as in A, following L5/S1 nucleotomy and instrumentation with Dynesys at L4–S1

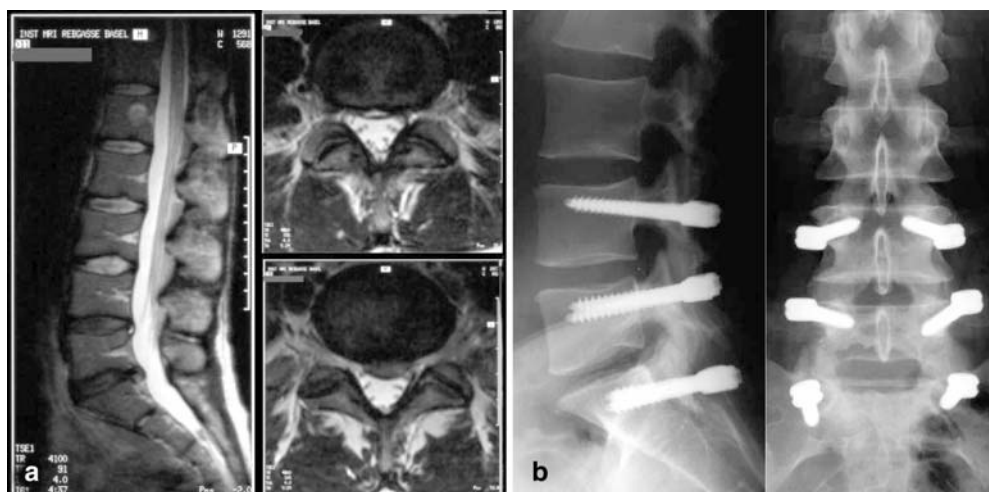


Fig. 2 A Preoperative myelographs of a 65-year-old man, demonstrating L4/5 dynamic stenosis with instability.

B Same patient as in A, following direct decompression and L4/5 instrumentation with Dynesys

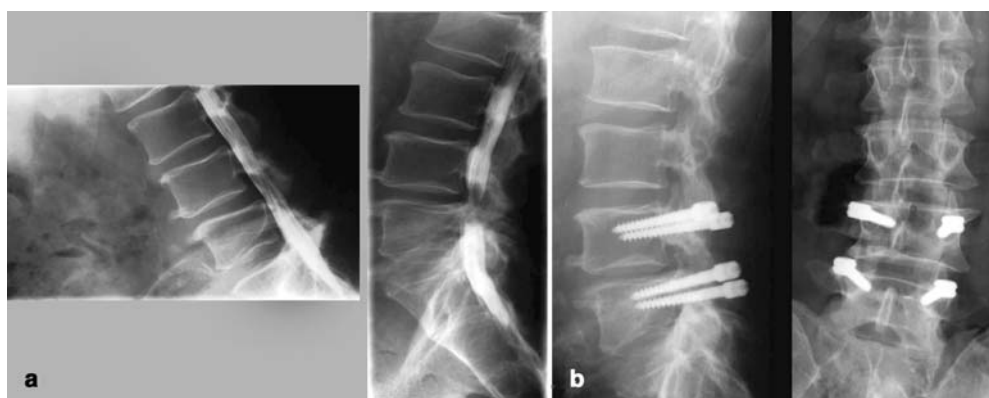
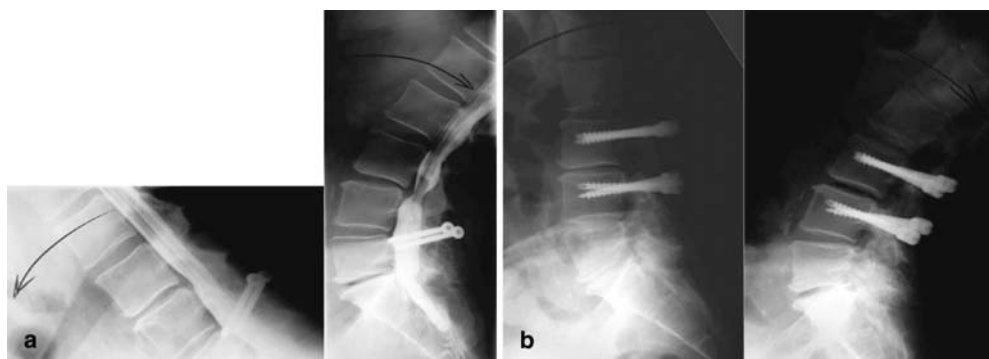


Fig. 3 A 56-year-old woman with previous postero-lateral fusion at L4/5 and L5/S1, instrumented with translaminar screws at L4/5. Myelography demonstrates dynamic stenosis at the adjacent L3/4 segment.

B Same patient as in A, 12 months after L4/5 screw removal, direct decompression and L3/4 Dynesys instrumentation. L3/4 angular motion is apparent



and facet joints. Postoperative bracing was applied only in exceptional cases.

Implants

The Dynesys system is composed of titanium alloy (Protasul 100) pedicle screws, polyester (Sulene-PET) cords, and polycarbonateurethane (Sulene-PCU) spacers (Fig. 5). The surface of the screw is sandblasted. The screws anchor the Dynesys system in the pedicle and in the vertebral body. The modular spacer fits between the pedicle screw heads. The stabilizing cord connects the pedicle screw heads via the hollow core of the spacer and holds the spacer in place. Its preload provides a uniform system rigidity. The stabi-

lizing cord carries tensile forces and the spacers resist compressive forces. The inherent stability of the whole construct also resists bending and shear forces.

Biomechanical testing

All components underwent various biomechanical and biological tests. This included fatigue testing of the whole construct for distraction and compression over 10 million cycles. The non-metallic parts were additionally tested in terms of biocompatibility.

In the majority of cases (66.3%), a monosegmental instrumentation was performed (Table 2). The most frequently instrumented segment was L4/5. Frequently, direct decompression was also per-

Fig. 4 Antero-posterior and lateral myelographs of L4/5 and L5/S1 stenosis in a 67-year-old woman. **B** Same patient as in **A**: antero-posterior and lateral standing radiographs following direct decompression and L4–S1 stabilisation with Dynesys

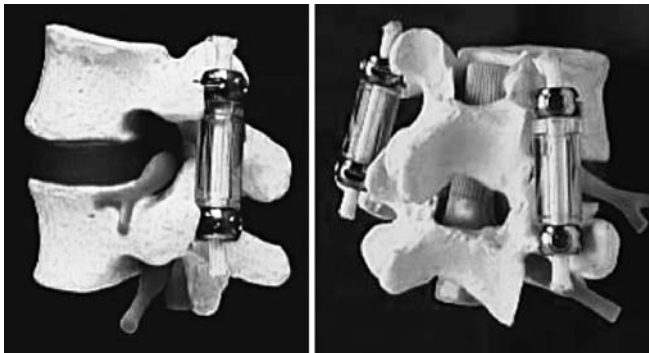
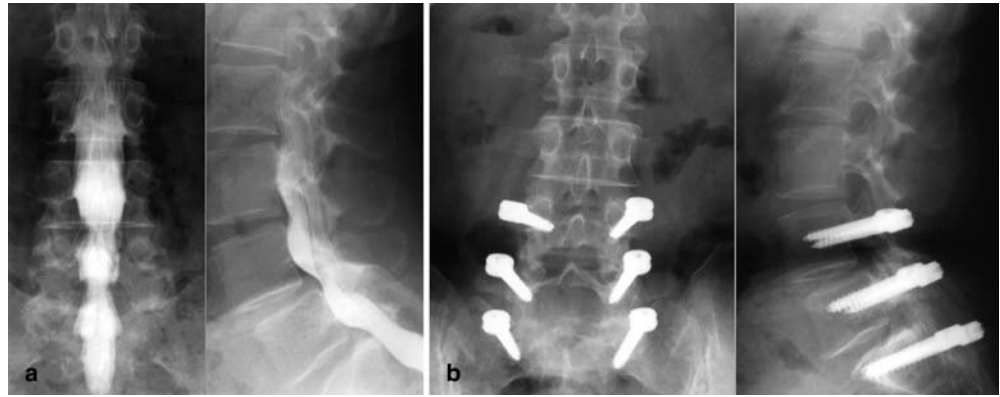


Fig. 5 Photographs of monosegmental Dynesys on a spine model

Table 2 Instrumented segments

| | <i>N</i> | % |
|---|----------|------|
| No. of levels treated | | |
| One | 55 | 66.3 |
| Two | 17 | 20.5 |
| Three | 8 | 9.6 |
| Four | 3 | 3.6 |
| Distribution of levels treated^a | | |
| L1/2 | 2 | 2.4 |
| L2/3 | 8 | 9.6 |
| L3/4 | 23 | 27.7 |
| L4/5 | 44 | 53.0 |
| L5/S1 | 6 | 7.2 |

^aHighest level treated for multi-level patients

Table 3 Additional procedures

| Additional procedure | <i>N</i> | % |
|-----------------------|----------|------|
| Direct decompression | 56 | 67.5 |
| Nucleotomy | 3 | 3.6 |
| Other | 8 | 9.6 |
| Decompression + Other | 1 | 1.2 |
| None | 15 | 18.1 |

formed, not only at the instrumented levels, but also at adjacent levels that were judged not to be unstable (additional procedures are shown in Table 3).

The mean duration of surgery was 163 min (± 58 min) and the mean blood loss was 407 cc (range 50–2500 cc).

Statistics

Statistics were calculated using the Statistica for Windows, by StatSoft, Inc. (2000).

Results

A total of 73 patients were available for follow-up. Two patients had died of non-related causes and eight patients had undergone implant removal for various reasons that are discussed later. The mean follow-up time was 38.1 months (range 11.2–79.1 months).

Complications

Complications were divided up into two groups. The nine complications unrelated to the implant were of usual quality and quantity (Table 4). One dural lesion necessitated a reoperation. In one case a paresis led to a revision (extension of instrumentation) 1 month postoperatively. Eventually, the cause of this progressive multilevel paresis was found to be a systemic non-Hodgkin lymphoma, and the patient died 4 months postoperatively of this disease. In one case a seroma had to be drained, and in another case a scar neuroma was excised.

Complications related to the implant included two screw misplacements; one patient had to be reoperated 2 weeks postoperatively because of root compression

Table 4 Complications unrelated to implant

| | |
|-------------------------|---------------------|
| Dural lesion | 2 (1 ^a) |
| Infection | 1 |
| Paresis | 1 ^a |
| Hypesthesia (resolving) | 1 |
| Seroma | 1 ^a |
| Scar neuroma | 1 ^a |
| Cardiovascular | 1 |
| Thromboembolism | 1 |

^aReoperated

Table 5 Complications related to implant

| | |
|--|---------------------|
| Pedicle fracture (intraop.) | 1 |
| Screw loosening | 1 ^a |
| Signs of screw loosening on radiograph | 7 |
| Screw malplacement | 2 (1 ^a) |

^aReoperated

signs (Table 5). The symptoms resolved soon after the reoperation.

In seven cases a screw loosening was suspected, based upon the radiological appearance of a screw halo or migration. In one case, a radiologically suspected screw loosening in combination with clinical symptoms necessitated a further intervention 14.5 months postoperatively. The loosening of two bilateral screws was confirmed and the screws were removed without re-stabilization.

Later, additional surgery

Apart from the above-mentioned reoperations due to complications, 11 patients needed additional lumbar surgery in the follow-up period (Table 6). In three cases with unresolved persisting pain the implant was removed, at 17.6, 18.8 and 39.7 months postoperatively, and in two of them a fusion was added. In one patient the index segment needed an additional laminectomy 22 months postoperatively.

Table 6 Later, additional surgery

| | |
|--|---|
| Complete implant removal | 8 |
| Dynesys extension (adjacent stenosis) | 2 |
| Decompression of adjacent segment (1 patient, later fused) | 2 |
| Laminectomy of index segment | 1 |

Table 7 Prolo functional status [32]

| Functional score | Preoperative | | Follow-up | |
|---|--------------|------|-----------|------|
| | N | % | N | % |
| Total incapacity | 35 | 47.9 | 2 | 2.7 |
| Back pain mild to moderate, able to perform all daily tasks of living | 19 | 26.0 | 13 | 17.8 |
| Low level of pain, able to perform all activities except sports | 19 | 26.0 | 23 | 31.5 |
| No pain, but patient has had one or more occurrences of back pain | – | – | 25 | 34.2 |
| No recurrent episodes of back pain, all previous sports/social activities | – | – | 10 | 13.7 |

Table 8 Prolo economic status

| Economic score | Preoperative | | Follow-up | |
|--|--------------|------|-----------|------|
| | N | % | N | % |
| Complete invalid | 7 | 9.6 | – | – |
| No gainful occupation (capable of indep. locomotion & self-care, unable to hold job, perform housework etc.) | 39 | 53.4 | 13 | 17.8 |
| Able to work | 21 | 28.8 | 27 | 37.0 |
| Working on part-time or limited status | 4 | 5.5 | 15 | 20.5 |
| Working with no restrictions of any kind | 2 | 2.7 | 18 | 24.7 |

In seven patients, adjacent segment degeneration necessitated further surgery. One of these patients underwent direct decompression procedures of the adjacent level at 11.3 and 24.7 months postoperatively, followed by implant removal and extended fusion 29.6 months postoperatively; four patients underwent implant removals and extended fusions at 5.8, 9.1, 15 and 17.6 months postoperatively, and two received extensions of the Dynesys instrumentation to an adjacent segment at 14.5 and 20.8 months postoperatively.

Radiological evaluation

The radiological evaluation revealed ten loose screws (in seven patients, including two removed screws) out of a total number of 280 screws (3.6%). Loose screws were defined as screws with a radiologically visible lytic zone (halo) and/or with migration. In all cases, the most cranial or/and most caudal screws were involved. Most loose screws appeared in early postoperative radiographs (less than 6 months postoperatively), and none appeared later than 1 year postoperatively.

Functional and economic status

The patients improved significantly in functional (Table 7) and economic (Table 8) status. However, the interpretation of these data is much restricted as a significant proportion of the patients were retired at the time of surgery.

Pain

The pain scale (visual analog scale 1–10) for low-back pain improved from a mean preoperative value of 7.4

(± 2.6) to a postoperative mean value of 3.1 (± 2.3). For leg pain, the preoperative value was 6.9 (± 3.0), which improved to 2.4 (± 2.1) at follow-up. The VAS for low-back pain and leg pain improved with a statistical significance ($P < 0.01$, Wilcoxon's matched-pair test).

Disability Index

The Oswestry Disability Index (ODI) is scored on a scale of 0–100%, where 0–20% means minimal disability, 20–40% means moderate disability, 40–60% means severe disability, 60–80% means crippled, and 80–100% means either bed-bound or exaggerating symptoms.

The preoperative mean Oswestry score was 55.4% ($\pm 19.5\%$, range 10–92%), which expresses a severe disability of the average patient. At follow-up it was 22.9% ($\pm 19.3\%$, range 0–71%), which expresses just a moderate disability of the average patient. This improvement was also statistically significant ($P < 0.01$). In patients with more than 2 years follow-up, the Oswestry score stayed at the same low level.

Discussion

Degenerative spondylosis can create spinal instability of various forms and characters. Instability can produce axial local low-back pain and pseudoradicular pain, as well as radicular pain and neurological deficit. Decompressive procedures may induce or increase instability [1, 5, 12, 20, 21]. In order to treat the various conditions degenerative spondylosis can create, surgical stabilization is frequently needed. Currently this is performed by some form of fusion (uninstrumented, instrumented, pedicular, PLIF, TLIF, ALIF). All these procedures have their specific disadvantages. They all generate a considerable amount of morbidity and high rates of complications [9, 27, 29, 31, 40, 41, 42, 43]. Moreover, fusion eliminates motion of the functional spinal segment and may overload the adjacent segments, thereby generating the "transition syndrome" and a high frequency of re-interventions [4, 23, 24, 33, 36, 37, 38].

These disadvantages lead to alternative procedures and techniques for stabilization without fusion – non-fusion systems.

Mobile stabilization systems have to neutralize noxious forces and restore normal function of the spinal segments on the one hand, and protect the adjacent segments on the other. Implants for a mobile connection have been proposed for intervertebral (disc arthroplasty), for transpedicular and for interspinous application. S en egas [39] introduced an interspinous system for stabilization following decompression procedures in spinal stenosis, with the main aim being the prevention of long, polysegmental fusions. Graf [15] introduced a transpedicular ligament re-

placement system for the treatment of painful degenerative disc disease, arousing many expectations [6, 26] that eventually probably can not be met [13, 17, 34]. The suggested action of this pedicle screw system was based upon the interlocking of the facet joints in maximal extension.

Dynesys is a pedicle system providing mobile stabilization controlling motion in any plane. It is designed for the treatment of degenerative conditions of the lumbar spine that present with unstable motion segments [11]. It aims at the restoration of stability in unstable conditions of degenerative origin, as presented by some forms of degenerative disc disease as well as unstable forms of lumbar stenosis, be this dynamic or permanent. Thus, indications are conditions of instability with local lumbar pain as well as radicular pain and/or deficit. Dynesys is also designed to stop further progression of minor deformity, which is frequently combined with spinal stenosis as, for instance, in degenerative spondylolisthesis, early degenerative scoliosis, and the combination of the two.

The posterior approach of the Dynesys is highly compatible with direct decompression procedures, and in the treatment of axial segmental pain it can be applied with less morbidity than a formal posterolateral fusion with pedicle instrumentation. It can also be applied through a Wiltse [44] approach, for less muscle damage, though in this series this approach was not used, as most cases needed additional direct decompression.

Interpretation of the results of the presented study must take into account some possible sources of bias; namely, it included the first series of patients operated with this technique, and therefore involved a learning curve, the average age of the patients was high, and 36.1% had undergone prior lumbar surgery.

This study on the efficacy and safety of this novel instrumentation includes a variety of diagnostic entities, among which the common denominator was a state of degenerative spondylosis. The main group, comprising patients with stenosis combined with some form of instability, is large enough ($n=50$, 60.2%) to offer a statistically valid database. While this is less true for the smaller subgroup of degenerative discopathy ($n=20$, 24.1%) and the other subgroups, some aspects of the study can nonetheless be used for comparison for these diagnostic subgroups as well.

The problem of all non-controlled clinical studies is the difficulty of comparing them with other similar series because important parameters are different. Nevertheless, it is still appropriate to compare some aspects of other studies with our own results. There are few studies published covering similar pathologies with fusion or pure decompression procedures. Many studies on pedicle fixation in non-traumatic pathologies include lytic spondylolisthesis, which we regard as a specific pathological entity with specific biomechanics. In 1999 the Chochrane Review of Surgery was still lamenting the absence of a randomized controlled study dealing with the surgical de-

compression of degenerative lumbar spondylosis or spinal stenosis [14], although the following year Amundsen [3] reported on the beneficial effects of decompressive surgery based on a randomized controlled study. Other randomized studies compared different surgical procedures for spinal stenosis [7, 10, 16, 18], which provide convincing evidence that, for spinal stenosis with instability and spondylolisthesis, fusion is beneficial, and this is clearly supported by the meta-analysis of Mardjetko et al. [25]. Hence, although there is excellent evidence that surgical decompression and added fusion for stenosis with degenerative spondylolisthesis is beneficial, it is debatable (evidence is sparse) whether added instrumentation is beneficial for this condition. And for this pathology, Dynesys may combine advantages, for instance by providing more stability than decompression alone, with being less invasive than instrumented fusion.

Invasiveness is reflected by morbidity. Morbidity generated by a procedure is expressed by the overall complication rate. With respect to morbidity, the mid-term results of this study compare favourably with fusion procedures. The overall complication rate in this study was 20 events in 83 patients (24%), but this includes seven cases with radiological signs of screw loosening at follow-up, of which probably only three are symptomatic, one case was reoperated prior to follow-up. The total complication rate also includes one complication that arose completely independent of the surgical procedure (rapidly developing systemic lymphoma). In a series of 107 patients with non-traumatic disorders treated with lumbar and lumbosacral fixation, Pihlajamäki et al. [31] reported 76 complications with 65 reoperations in an average follow-up period of 40 months. This high percentage may be partially explained by the inclusion of 40 cases of spondylolysis with listhesis. In a selected survey of ABS (American Board of Surgeons) members, looking at complications in 617 cases of pedicle screw fixation, Esses et al. [9] reported a total of 169 (27.4%) complications. In a series of 148 cases (79 with degenerative listhesis) treated with PLIF and pedicle fixation, Okuyama et al. [29] actually reported 91 complications in 75 cases.

Of the nine non-implant related complications in our series, some are of minor importance and none of them are severe. They compare favorably with other studies on similar pathologies and are rather few in number, bearing in mind the elevated age of the patients – a fact that supports Dynesys as a less invasive procedure than fusion.

The low rate of infections (there was only one and it was superficial), and the lack of serious cardiovascular complications in our series may be explained by the fact that Dynesys is less invasive as compared with most posterior fusion procedures. There are three main reasons for this. First, there is no need for graft site preparation with posterolateral enlargement of the soft tissue damage and no harvest site morbidity. Second, it is more rapidly per-

formed. Third, it allows the treatment of degenerative lumbar disease in a segment by segment manner. This means that with multisegmental degeneration, the stabilizing procedure can be restricted to one segment above or below a degenerative but stable segment – a decision that would not be considered with fusion, resulting in the extremely invasive, and probably unnecessary, extensions of fusions frequently observed.

The rate of implant-related complications was also moderate in this series [42]: two screw malpositionings, one intraoperative pedicle fracture, seven cases of radiographic screw loosening and one case of confirmed screw loosening, which had to be reoperated. The rate of pedicle screw misplacement in this series is low [2, 9, 43], but this is independent of the specific qualities of Dynesys and probably reflects the experience of the three surgeons, as no procedure was performed with the help of a computed navigation system.

In this series, no screw breakage was observed. This compares favorably with rates recorded for rigid pedicle systems [28, 29, 31, 40]. Reason for this may be the elasticity of the spacer/cord compound, which may cause cyclic peak loads on the implant to be lower than in rigid constructs.

Screw loosening was defined as the radiological appearance of halo formation and/or screw migration. This was observed in seven patients (including one patient in whom screws at a different site had previously been removed bilaterally). Only one of these patients had to be reoperated, and six of them had no accompanying symptoms and a low level of pain.

This screw-loosening rate seems to be similar or even low compared with studies on rigid pedicle instrumentations. In the above-mentioned study of Pihlajamäki et al. [31], of 102 cases 18 showed screw loosening, one screw bending and 20 screw breakage. Ohlin et al. [28] reported implant failure in 64 of 163 procedures (153 patients). Soini et al. [40] reported screw breakage in eight and screw loosening in 14 of 51 patients with listhetic and degenerative conditions of the spine. Adding an anterior, intervertebral support to the pedicle instrumentation certainly lowers the rate of screw loosening and breakage, as the above-mentioned study of Okuyama et al. [29] reports, but it increases the rate of other complications and morbidity.

As Dynesys is a prosthetic device that theoretically ought to act as such for the remaining life-time, screw loosening deserves special analysis. Implant loads in a segmental lumbar setting are of high complexity [35]. It is hypothesized that, due to its lower stiffness, Dynesys and therefore also the screw-bone interface may see less load than conventional internal fixator systems. But load transfer is substantially different, since the screws are not rigidly linked by a rod. Screws radiologically presenting with a halo may be surrounded by fibrous tissue withstanding the cyclic load and preventing any further pro-

gression of the loosening. However, the appropriate amount of interface loading for optimal initiation of bone formation around the screw is not known and needs to be subjected to further research. Some loosening in this series is probably due to technical faults in the preparation of the screw hole and positioning of the screw (depth of placement, manipulation while inserting cord), and some may be due to incorrect choice of screw dimensions, as until December 1998 only two screw widths were available. This judgement is based on two observations: First, screw loosening seems to develop very early, as the authors made the observation that the halo appeared in early postoperative radiographs (less than 6 months postoperatively), and with one exception it never appeared later in the course. Second, the rate of loosening seems to have decreased with the growth of the series, which expresses aspects of the learning curve and the availability of a wider choice of screw dimensions.

Reoperations and later, additional surgery

Reoperations for complications were necessary in six cases. They were either unrelated ($n=4$) or related ($n=2$) to the implant. This has been discussed above. Later additional surgery was performed in a total of 11 patients. In three patients, Dynesys was removed and a fusion procedure was performed because of persisting low-back pain. One patient had undergone two decompression procedures before the removal. The most frequent cause for later additional surgery (nine in 13 events or seven in 11 patients) in this series was adjacent segment degeneration. Some of these segments had been decompressed at the initial operation, and some had not. The main question remains, however: in which cases was the development of adjacent stenosis due to the natural progression of the disease (degenerative lumbar stenosis) and in which was it due to transferred overload? Studies on fusions provide much evidence of the overload sequelae [4, 23, 33, 36, 37,

38], but are not comparable because of different study parameters. A reduction of acceleration of adjacent segment degeneration with Dynesys can theoretically be stated on the basis of the protective effect of persisting segmental motion. Based upon the number and the follow-up time of this series, a reduction of acceleration of adjacent segment degeneration cannot be proven. However, with respect to adjacent degeneration, it has to be emphasized that it is under any circumstances very difficult to differentiate the degeneration rate due the natural course of the disease from the one that is due to acceleration of this process by the elevated load transfer or other factors related to the procedure and the instrumentation. The iatrogenic contribution to this process could perhaps be defined statistically only in large comparative, randomized series, which are not available to date. This is especially true in the age group and the specific selection of indications of this study. The progressive natural history of plurisegmental degenerative lumbar disease challenges the result of any kind of surgical treatment.

Conclusions

This study proves Dynesys to be a safe and efficient procedure for stabilization of unstable conditions of the lumbar spine presenting with neurocompression. The mid-term results are highly comparable to fusion procedures, with the difference that Dynesys is less invasive and theoretically produces less degeneration of adjacent segments in the long term.

Dynesys allows the treatment of degenerative lumbar disease in a segment by segment manner. In early stages, as well as in more advanced stages of degeneration of the motion segment, Dynesys re-establishes stability.

Acknowledgements The authors are grateful to Ms Elke Rometsch, Sulzer Medica, for the excellent preparation of the data base and the extensive statistical analysis. They thank Mark Myers MD, Minneapolis, for the radiological evaluation at follow-up.

References

1. Abumi K, Panjabi MM, Kramer KM, Duranceau J, Oxland T, Crisco JJ (1990) Biomechanical evaluation of lumbar spine stability after graded facetectomies. *Spine* 15:1142–1147
2. Amiot LP, Lang K, Putzier M, Zippel H, Labelle H (2000) Comparative results between conventional and computer-assisted pedicle screw installation in the thoracic, lumbar, and sacral spine. *Spine* 25:606–614
3. Amundsen T, Weber H, Nordal HJ, Magnaes B, Abdelnoor M, Lilleas F (2000) Lumbar spinal stenosis: conservative or surgical management? *Spine* 25:1424–1436
4. Aota Y, Kumano K, Hirabayashi S (1995) Postfusion instability at the adjacent segments after rigid pedicle screw fixation for degenerative lumbar spinal disorders. *J Spinal Disord* 8: 464–473
5. Boden SD, Martin C, Rudolph R, Kirkpatrick JS, Moeini SMR, Hutton WC (1994) Increase of motion between lumbar vertebrae after excision of the capsule and cartilage of the facets. *J Bone Joint Surg Am* 76:1847–1853
6. Brechbühler D, Markwalder TM, Braun M (1998) Surgical results after soft system stabilization of the lumbar spine in degenerative disc disease – long term results. *Acta Neurochir* 140: 521–525
7. Bridwell KH, Sedgewick TA, O'Brien MF, Lenke LG, Baldus C (1993) The role of fusion and instrumentation in the treatment of degenerative spondylolisthesis with spinal stenosis. *J Spinal Disord* 6:461–472

8. Dubois G, de Gernay B, Schaerer NS, Fennema P (1999) Dynamic neutralization: a new concept for restabilization of the spine. In: Szpalski M, Gunzburg R, Pope MH (eds) Lumbar segmental instability. Lippincott Williams & Wilkins, Philadelphia, pp 233–240
9. Esses SI, Sachs BL, Dreyzin V (1993) Complications associated with the technique of pedicle screw fixation. *Spine* 18:2231–2239
10. Fischgrund JS, Mackay M, Herkowitz HN, Brower R, Montgomery DM, Kurz LT (1997) Volvo Award Winner in Clinical Studies. Degenerative lumbar spondylolisthesis with spinal stenosis: a prospective, randomized study comparing decompressive laminectomy and arthrodesis with and without spinal instrumentation. *Spine* 22:2807–2812
11. Freudiger S, Dubois G, Lorrain M (1999) Dynamic neutralisation of the lumbar spine confirmed on a new lumbar spine simulator in vitro. *Arch Orthop Trauma Surg* 119:127–132
12. Frymoyer JW, Selby DK (1985) Segmental instability. Rationale for treatment. *Spine* 10:280–286
13. Gardner AD, Pande KC, Hassaan AM, Declerck G (1999) Graf stabilization of intractable lumbar instability syndrome. In: Szpalski M, Gunzburg R, Pope MH (eds) Lumbar segmental instability. Lippincott Williams & Wilkins, Philadelphia, pp 175–190
14. Gibson JNA, Grant IC, Waddell G (1999) The Cochrane review of surgery for lumbar disc prolapse and degenerative lumbar spondylosis. *Spine* 24:1820
15. Graf H (1992) Lumbar instability: surgical treatment without fusion. *Rachis* 412:123–137
16. Grob D, Humke T, Dvorak J (1995) Degenerative lumbar spinal stenosis. *J Bone Joint Surg Am* 77:1036–1041
17. Hadlow SV, Fagan AB, Hillier TM, Fraser RD (1998) The Graf ligamentoplasty procedure – comparison with posterolateral fusion in the management of low back pain. *Spine* 23:1172–1179
18. Herkowitz HM, Kurz LT (1991) Degenerative lumbar spondylolisthesis with spinal stenosis: a prospective study comparing decompression and intertransverse arthrodesis. *J Bone Joint Surg Am* 73:802–808
19. Husson JL, Poncer R, Polard JL (1996) Dérangement intervertébral acquis (DIVA). In: Husson JL, Le Huec JC (eds) Restabilisation intersomatique du rachis lombaire. Sauramps Medical, Montpellier, pp 13–21
20. Johnsson KE, Willner S, Johnsson K (1986) Postoperative instability after decompression for lumbar spinal stenosis. *Spine* 11:107–110
21. Jönsson B, Akesson M, Jonsson K, Strömquist B (1992) Low risk for vertebral slipping after decompression with facet joint preserving technique for lumbar spinal stenosis. *Eur Spine J* 1:100–104
22. Kirkaldy-Willis WH, Farfan HF (1982) Instability of the lumbar spine. *Clin Orthop* 165:110–123
23. Kumar MN, Jacquot F, Hall H (2001) Long-term follow-up of functional outcomes and radiographic changes at adjacent levels following lumbar spine fusion for degenerative disc disease. *Eur Spine J* 10:309–313
24. Lehmann TR, Spratt KF, Tozzi JE, Weinstein JN, Reinartz SJ, El-Khoury GY, Colby H (1987) Long-term follow-up of lower lumbar fusion patients. *Spine* 12:97–104
25. Mardjetko SM, Connolly PJ, Shott S (1994) Degenerative lumbar spondylolisthesis. *Spine* 19:S2256–S2265
26. Markwalder TM, Dubach R, Braun M (1995) Soft system stabilization of the lumbar spine as an alternative surgical modality to lumbar arthrodesis in facet syndrome. Preliminary results. *Acta Neurochir* 134:1–4
27. Matsuzaki H, Tokuhashi Y, Matsumoto F, Hoshino M, Kiuchi T, Toriyama S (1990) Problems and solutions of pedicle screw plate fixation of lumbar spine. *Spine* 15:1159–1165
28. Ohlin A, Karlsson M, Düppe H, Hassserius R, Redlund-Johnell I (1994) Complications after transpedicular stabilization of the spine. *Spine* 19:2774–2779
29. Okuyama K, Abe E, Suzuki T, Tamura Y, Chiba M, Sato K (1999) Posterior lumbar interbody fusion. *Acta Orthop Scand* 70:329–334
30. Panjabi MM (1992) The stabilizing system of the spine. 2. Neutral zone and instability hypothesis. *J Spinal Disord* 5: 390–397
31. Pihlajamäki H, Myllynen P, Böstman O (1997) Complications of transpedicular lumbosacral fixation for non-traumatic disorders. *J Bone Joint Surg Br* 79:183–189
32. Prolo DJ, Oklund SA, Butcher M (1986) Toward uniformity in evaluating results of lumbar spine operations. A paradigm applied to posterior lumbar interbody fusions. *Spine* 11:601–606
33. Rahm MD, Hall BB (1996) Adjacent-segment degeneration after lumbar fusion with instrumentation: a retrospective study. *J Spinal Disord* 9:392–400
34. Rigby MC, Selmon GPF, Foy MA, Fogg AJB (2001) Graf ligament stabilisation: mid- to long-term follow-up. *Eur Spine J* 10:234–236
35. Rohlmann A, Graichen F, Weber U, Bergmann G (2000) 2000 Volvo Award winner in biomechanical studies. Monitoring in vivo implant loads with a telemeterized internal spinal fixation device. *Spine* 25:2981–2986
36. Schären S, Dick W (1998) Erfolge und Probleme langstreckiger Fusionen der degenerativen Lendenwirbelsäule. *Osteosynthese Int* 6:173–179
37. Schlegel JD, Smith JA, Schleusener RL (1996) Lumbar motion segment pathology adjacent to thoracolumbar, lumbar and lumbosacral fusions. *Spine* 21:970–981
38. Schulitz KP, Wiesner L, Wittenberg RH, Hille E (1996) Das Bewegungssegment oberhalb der Fusion. *Z Orthop* 134:171–176
39. Senegas J, Etchevers JP, Vital JM, Baulny D, Grenier F (1988) Widening of the lumbar vertebral canal as an alternative to laminectomy in the treatment of lumbar stenosis. *Fr J Orthop Surg* 2:93–99
40. Soini J, Laine T, Pohjolainen T, Hurri H, Alaranta H (1993) Spondylodesis augmented by transpedicular fixation in the treatment of olisthetic and degenerative conditions of the lumbar spine. *Clin Orthop* 297:111–116
41. Turner JA, Ersek M, Herron L, Haselkorn J, Kent D, Ciol M, Deyo R (1992) Patient outcomes after lumbar spinal fusions. *JAMA* 268:907–911
42. Turner JA, Herron L, Deyo RA (1993) Meta-analysis of the results of lumbar spine fusion. *Acta Orthop Scand [Suppl 251]* 64:120–122
43. West JL, Ogilvie JW, Bradford DS (1991) Complications of the variable screw plate pedicle screw fixation. *Spine* 16:576–579
44. Wiltse LL, Spencer CW (1988) New uses and refinements of the paraspinous approach to the lumbar spine. *Spine* 13:1008–1012