

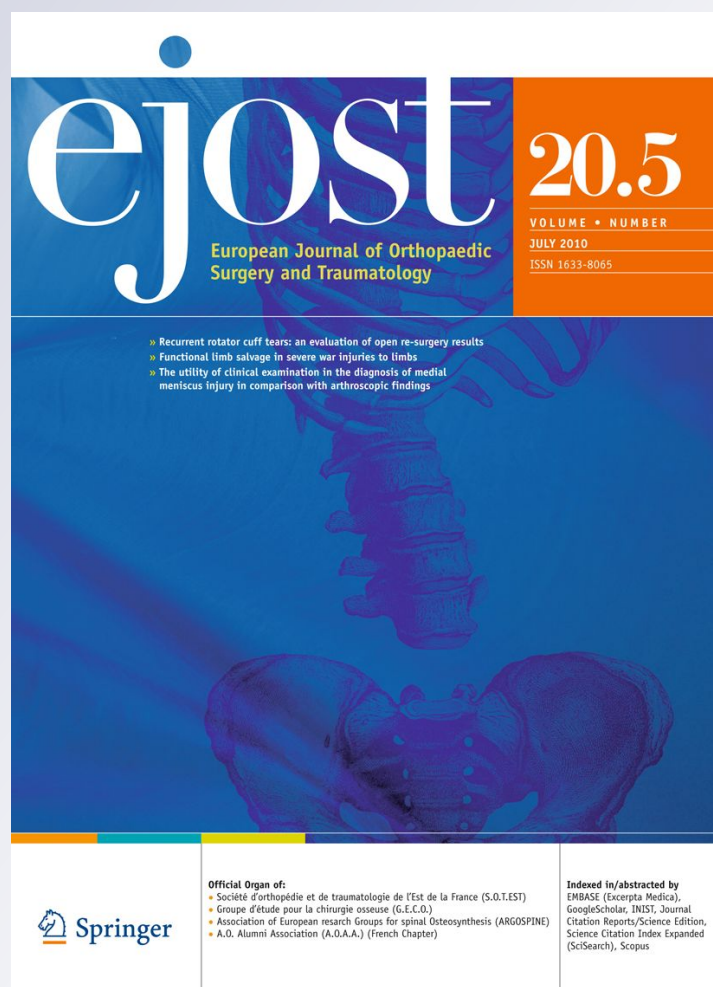# *A new approach in the miniminvasive treatment of fractures*

*Stefan Cristea, F. Groseanu,  
A. Prundeanu, V. Predescu, M. Gavrilă,  
D. Gartonea & A. Papalici*

**European Journal of  
Orthopaedic Surgery &  
Traumatology**

ISSN 1633-8065

Eur J Orthop Surg Traumatol  
DOI 10.1007/  
s00590-011-0838-2



**Your article is protected by copyright and all rights are held exclusively by Springer-Verlag. This e-offprint is for personal use only and shall not be self-archived in electronic repositories. If you wish to self-archive your work, please use the accepted author's version for posting to your own website or your institution's repository. You may further deposit the accepted author's version on a funder's repository at a funder's request, provided it is not made publicly available until 12 months after publication.**

## A new approach in the miniminvasive treatment of fractures

Stefan Cristea · F. Groseanu · A. Prundeanu ·  
V. Predescu · M. Gavrilă · D. Gartonea ·  
A. Papalici

Received: 31 March 2011 / Accepted: 25 June 2011  
© Springer-Verlag 2011

**Abstract** The use of biological cement with provisory closed percutaneous Kirschner wire (K-wire) fixation enabled the treatment of 12 patients with fractures. Within the period November 2010—February 2011, we have treated at Saint Pantelimon Emergency Orthopaedics Clinic 12 patients using this specific method, namely: 8 humeral fractures, 1 distal radial fracture, 1 distal radial fracture associated with carpal scaphoid fracture, 1 ankle fracture, and a delayed union of distal tibial fracture. In the specialized literature, the use of bone substitutes or of biological bone cement has never been described in the treatment of fractures without the opening of the fracture site. Some bone fillers for bone defects have been injected before, together with osteosynthesis means, plates and screws, respectively. The assessment of the results has to take into account the consolidation range of each type of fracture, and the cast fixation must be extended accordingly. The recovery shall depend upon the fracture's callus biology, the fracture's type and location as well as the age of the patient. We evaluate the results after clinical and radiological criteria. Consolidation was achieved in all cases. We will present also the complications related to first use of this new method. The use of Kryptonite-X injected under fluoroscopic control in the conservative treatment of the fractures is a novelty. Thus, it is introduced the perspective of an innovative way of treating the fractures. Consolidation was achieved in all cases.

**Keywords** Biological cement · Conservative treatment of the fractures · Percutaneous · Osteosynthesis · Osteointegration

### Aim

Orthopedic surgeons have always tried a conservative treatment of fractures. The application of such treatment is difficult, requiring a long period of immobilization and the results are inaccurate. The injection of biological factors, of recombinant human bone morphogenetic protein (rhBMP), in the fracture site, together with some osteosynthesis means has been performed before, but without spectacular results. The injectable bone void fillers have been used to stabilize screws or nails, such as hydroset, norian, glass ceramics, and plaster. The use of a substance that actions like a glue, but in the same time, it will be osteointegrated is very attractive. We have chosen the injection of Kryptonite-X as biological cement and as glue.

The use of biological osteoinductive, osteoconductive cement, along with temporary fixation provides consolidation without classical surgical intervention. The presence of Kryptonite-X biological cement in the fracture site or in the surrounding soft tissues should not give foreign body reaction, but it should ensure both inter fragmentary fixation and its osteointegration.

### Method

In the specialized literature, the use of bone substitutes or of biological bone cement has never been described in the treatment of fractures without the opening of the fracture

S. Cristea (✉) · F. Groseanu · A. Prundeanu · V. Predescu ·  
M. Gavrilă · D. Gartonea · A. Papalici  
Department of Orthopaedic Surgery,  
Emergency Hospital Saint Pantelimon Sos,  
Pantelimon 344, sect 2, 021623 Bucuresti, Romania  
e-mail: drstefancristea@yahoo.com

**Table 1** Case group

Patient	Fracture type	Removal of external fixation	Consolidation period weeks	Functional recovery weeks	Complications	Removal of Kryptonite
1.	Humeral shaft fracture	6 week	8	Complete within 8 week	–	–
2.	Humeral shaft fracture	7 week	10	Complete within 12 week	Soft tissue injection and secondary septic reaction	7 week
3.	Humeral shaft fracture	7 week	9	Complete within 10 week	–	–
4.	Humeral shaft fracture	6 week	8	Complete within 9 week	–	–
5.	Humeral neck fracture	4 week	4	Complete within 7 week	–	–
6.	Humeral neck fracture	6 week	6	Complete within 8 week	–	–
7.	Humeral neck fracture	4 week	5	Complete within 7 week	–	–
8.	Humeral neck fracture— dislocation	3 week + 4 week	7	Complete within 8 week	–	–
9.	Distal radial fracture	6 week	6	Complete within 8 week	–	–
10.	Distal radial fracture Carpal scafoïd fracture	4 week + 5 week	8	Complete within 10 week	Soft tissue injection and CRPS	5 week
11.	Ankle fracture— hyperparathyroidism	–	12	Complete within 16 week	–	–
12.	Delayed union of distal tibial fracture	–	12 week after Kryptonite injection	80% within 12 week	–	–

site. Some bone fillers for bone defects have been injected before, together with osteosynthesis means, plates and screws, respectively [1–4].

We have chosen the injection of Kryptonite-X as biological cement and as glue. The inconvenient of slow achievement of the mechanical resistance has been compensated by the use of temporary percutaneous K-wire fixation.

We used the percutaneous injection of biological cement in the fracture site after the fracture reduction along with provisory closed percutaneous K-wire fixation for the treatment of 12 patients with fractures.

Within the period November 2010–February 2011, we have treated at Saint Pantelimon Emergency Orthopaedics Clinic 12 patients using this specific method, namely: 8 humeral fractures: 4 humeral shaft fractures and 4 humeral neck fractures, of which one fracture dislocation; 1 distal radial fracture; 1 distal radial fracture associated with carpal scaphoid fracture; 1 ankle fracture; and 1 delayed union of distal tibial fracture—Table 1.

Under fluoroscopic control of the reduction and temporary K-wire fixation, we have injected percutaneous biological cement in the fracture site with 18 G needles, Fig. 1.

We used “KRYPTONITE-X”, biological liquid, radiopaque cement that hardens in 15–25 min.

This consists of:

- Component A—Prepolymer (73% phenylisocyanat), polyol castor oil 24%, and 3% polypropylene carbonate;

- Component B—Polyol castor oil 96%, 4% ricinoleic acid, and catalyst 1%;
- Component C—Ca carbonate 33% and 67% barium sulfate.

The three components mix for 1 min, then polymerize within 3 min.

For 3–8 min, the compound remains in liquid state, so that it can be injected in maximum 8 min. One should note that in this stage, its volume doubles and an exothermic reaction takes place with a maximum of 43°C.

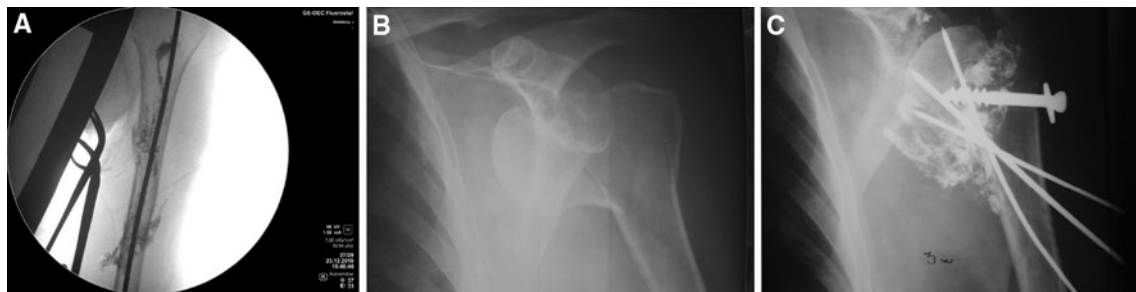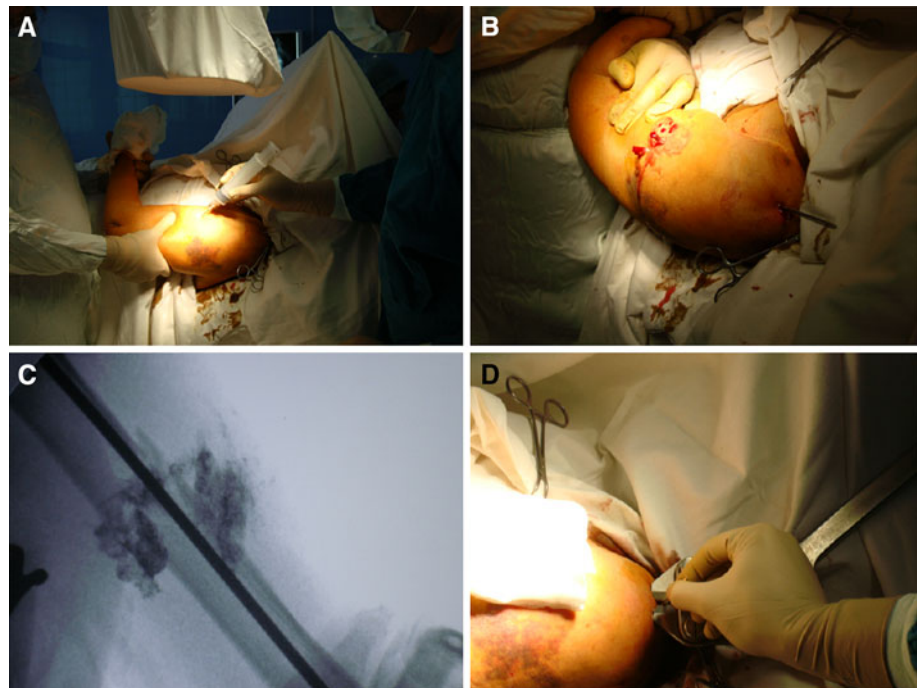
The compound is moldable for 15 up to 25 min and within 24 h it obtains an 80% bone-like resistance.

The injection of biological cement should be made under fluoroscopic control in order to properly fill the fracture site and to prevent its migration into the soft tissues. This method uses Kryptonite-X as superglue, as biological cement which does not imply removal because it is osteointegrated.

## Results

The assessment of the results has to take into account the consolidation range of each type of fracture, and the cast fixation must be extended accordingly. The recovery shall depend upon the fracture's callus biology, the fracture's type and location as well as the age of the patient.

**Fig. 1** Reduction (a) and temporary osteosynthesis, the placement of the needles in the fracture site (b), X-ray control (c), K-wire cutting at the edge of the bone (d)



**Fig. 2** a Humerus shaft fracture—reduction, 18 G needle placement, cement injection, b Fracture dislocation—orthopaedic reduction, and percutaneous X-ray osteosynthesis at 3 weeks (c)

The humeral shaft fractures have consolidated between 8 and 10 weeks, and the patients have fully regained the mobility of the shoulder and elbow in maximum 3 months. The shoulder fracture dislocation including the scapulo-humeral joint needed a temporary fixation for 3 weeks with K-wires. For the humeral neck fracture, the consolidation was obtained in 4–6 weeks. The full recovery of the shoulder was obtained in 2 months Fig. 2.

The ankle fracture was on pathologic bone due to a secondary hyperparathyroidism. In this case, we filled the peroneal bone defect with Kryptonite through open reduction with plate and screws. The patient was further diagnosed and treated by an endocrinologist surgeon. The ankle fracture has consolidated in 3 months when full bearing gait was allowed.

The distal radial fracture was associated with a carpal scaphoid fracture. The orthopaedic reduction, the percutaneous temporary fixation with K-wires of the 2 fractures, and the percutaneous injection under fluoroscopic control

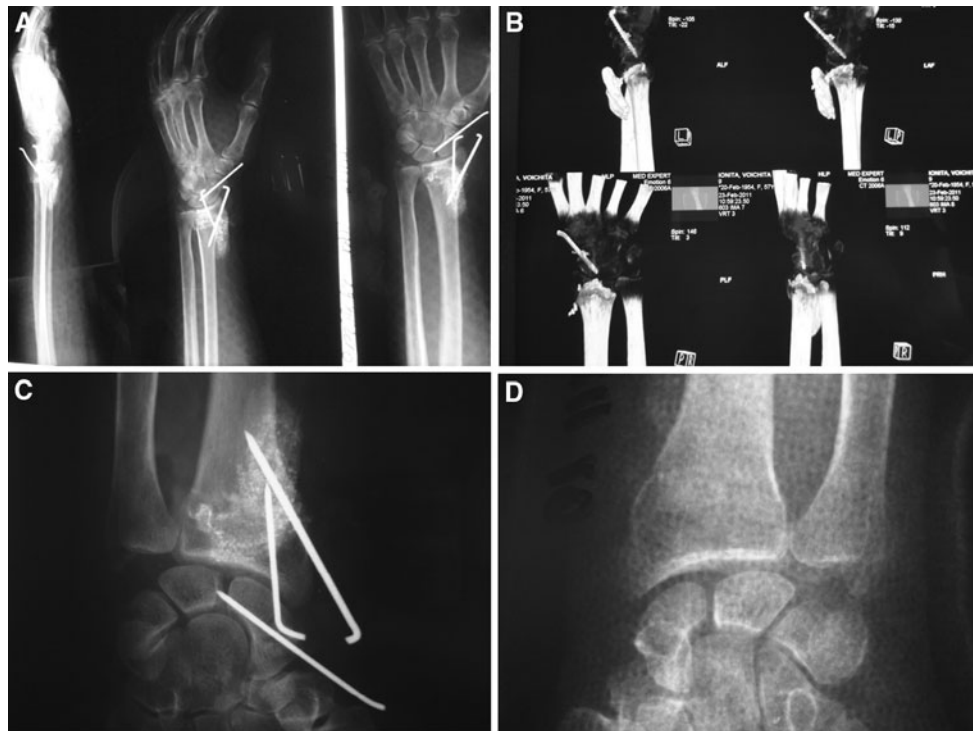
of Kryptonite resulted in a 2 months consolidation period (Fig. 3).

In two cases, Kryptonite has accidentally elapsed between soft tissues during injection, the supplier of this product ensuring us that there would be no further problem.

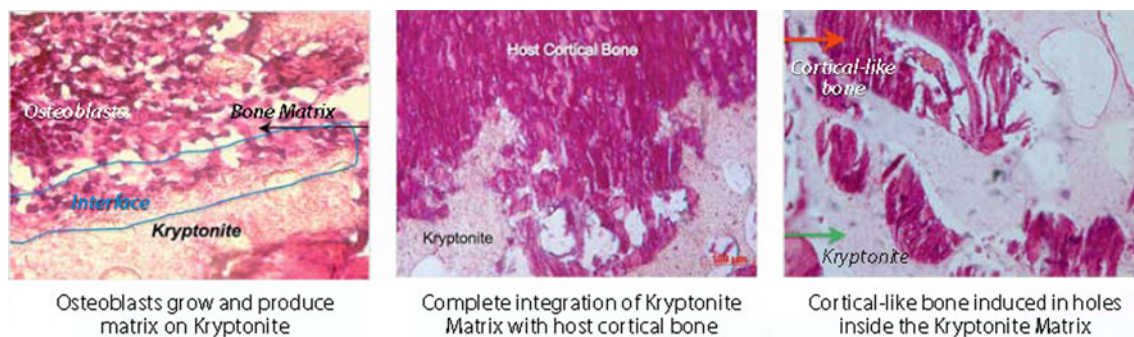
One of them had a local septic response and cleaning measures included removal of cement.

The other case suffered from a complex regional pain syndrome (CRPS) of the wrist and the removal of the cement led to healing. These cases have favored the histological analysis of cement and soft tissues at 5 and 7 weeks after injection. The injection into soft tissue of small quantities of cement does not raise special problems.

The removal of Kryptonite-X was necessary only when the injected cement elapsed outside the fracture site inducing impingement or conflict with the surrounding soft tissue. Complications were due to the establishment and adjustment of the surgical technical details during the treatment.



**Fig. 3** Distal radial fracture associated with a carpal scaphoid fracture—orthopaedic reduction, percutaneous temporary fixation with K-wires of the 2 fractures (a), CT control (b), X-ray control (c), and final result (d)



**Fig. 4** The histological data confirm complete integration of Kryptonite Matrix in femoral defect in mouse at 1 year—[1]

Bone consolidation has been achieved in all cases. The delayed union of distal tibial fracture has consolidated 3 months after injection, and walking with free-loaded orthosis was allowed.

Unfortunately, the building phase of the substance is being obtained in 20–30 min, during which we must hold firm and maintain fracture reduction.

It is this why we inserted percutaneous K-wires after reduction under fluoroscopic control, to facilitate the procedure. After installing the 18 G needles in the fracture site under fluoroscopic control, the substance is being injected in liquid form, firmly immobilizing the fracture. One must make sure the substance does not elapse excessively

between soft tissues. There are thus obtained bone welding spots that will allow the biological consolidation process of bone. Callus formation is variable depending upon the fracture's type and the patient's age. It is required that the immobilization is maintained until consolidation, either with K-wires or plaster casts or orthosis devices. The histological data confirm complete integration of Kryptonite Matrix (Fig. 4).

The discovery of new substances may enable the future achievement of a rapid intimate and resistant inter fragmentary fracture contact, without the need for temporary immobilization of the fracture to allow the biology of the callus to facilitate the osteointegration of the injected substance.

## Conclusions

The use of Kryptonite-X injected under fluoroscopic control in the conservative treatment of the fractures is a novelty. It is thus introduced the perspective of an innovative way of treating fractures. Consolidation has been achieved in all cases.

Complications were due to the establishment and adjustment of the surgical technical details during the treatment.

The discovery of new substances may enable the future achievement of a rapid intimate and resistant inter fragmentary fracture contact, without the need for temporary immobilization of the fracture to allow the biology of the callus to facilitate the osteointegration of the injected substance.

**Conflict of interest** None.

## References

1. Adams DJ, Barrero M, Jiang X, Roew DW (2008) Persistent osteoconductivity of calcium triglyceride bone cement in osteoporotic bone—54 th annual meeting of the orthopaedic research society, San Francisco, 2–5 Mar 2008. 33:1711
2. Vallittu PK, Mitteenen V, Alakujaila P (1995) Residual monomer content and its release into water from denture base materials. *Dent Mater* 11:33842
3. Zins JE, Moreira-Gonzalez A, Papay FA (2007) Use of calcium-based bone cements in the repair of large, full-thickness cranial defects: a caution. *Plast Reconstr Surg* 120(5):1332–1342
4. Fedak P, Kolb E, Borsato G et al (2010) Kryptonite bone cement prevents pathologic sternal displacement. *Ann Thorac Surg* 90:979–985